


OPTICAL COHERENCE TOMOGRAPHY

The Quick Guide to OCT Mastery 50 Real Cases with Expert Analysis

VOL 1



Sanjay Sharma, MD, FRCS, MSc (Epid), MBA
Ophthalmologist, Epidemiologist
Queen's University, Canada

Cost Effective Health Care Inc.

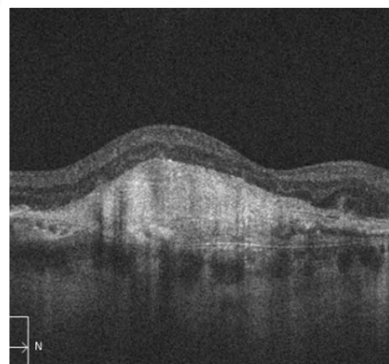
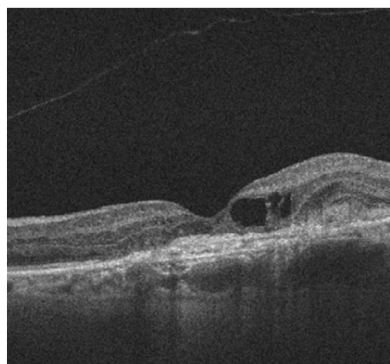
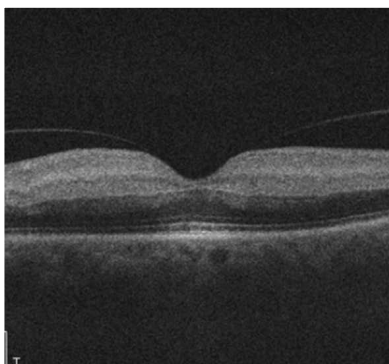
The Quick Guide to OCT Mastery is the first in a series of volumes on the real life reading of Optical Coherence Tomography (OCT) scans. Each case is shown with short patient history and an unlabeled scan image to give you a chance to test yourself. The analysis follows with the same scan clearly marked to tie in to the analysis commentary.

Each case includes an “OCT Tip” and a recommendation for follow-up or referral.

There are 50 cases covering a range of typical cases that a clinician is likely to see in an eye care clinic.

The cases are suitable for any level but will benefit those who want to understand a range of real life OCT results as they are obtained and presented in clinic.

This volume contains 50 cases and over 100 images.



Dr Sanjay Sharma is a highly regarded retina specialist in Kingston, Ontario, Canada and has over 20 years of experience as an ophthalmologist and retina specialist. Dr Sharma is a professor in ophthalmology and epidemiology at Queen’s University in Kingston, Ontario Canada. Dr Sharma is Editor-in-Chief of Optocase.com and medskl.com.

OPTICAL COHERENCE TOMOGRAPHY

The Quick Guide to OCT Mastery

50 Real Cases with Expert Analysis

VOL 1

Dr. Sanjay Sharma, M.D., BSc (Epid)

Ophthalmologist, Epidemiologist

Queen's University, Canada

Cost Effective Health Care Inc.

NOTICE TO READER

This book is designed to provide practical advice to those viewing and interpreting OCT scans in their daily practice. The example scans in each case have been carefully chosen to illustrate cases that have value in everyday practice.

This book has been written based on the training and knowledge of those involved. We have made every effort to ensure the accuracy of the content. However, medical knowledge changes constantly and we recommend that readers make sure they have the most up to date information when reading, interpreting and acting on their analysis of OCT scans.

It is the responsibility of the medical practitioner to rely on more than just this book in their assessment of patients, their analysis of OCT scans and the resulting action that they take in diagnosing, treating and referring patients.

Cost Effective Health Care Inc.

427 Princess Street, Suite 115
Kingston, Ontario, K7L 5S9, Canada
Email: support@optocase.com

All rights reserved. No part of this publication may be reproduced or transmitted in any form or by any means, whether electronic or mechanical, including photocopying, photographing, scanning or any other copying process without permission in writing from Cost Effective Health Care Inc.

OPTICAL COHERENCE TOMOGRAPHY

The Quick Guide to OCT Mastery, Vol. 1:

50 Real Cases with Expert Analysis

© 2016, Cost Effective Health Care Inc.

I.S.B.N. 978-0-9731661-1-8

To Neel whose grit is unparalleled;
to Evan whose vibrant dream is breathtaking;
and to Susan whose love I cherish.

CONTENTS

Glossary	vi
1. The external limiting membrane (ELM) and ellipsoid zone (EZ).....	1
2. Retinal pigment epithelium (RPE) bumps.....	3
3. How to predict vision from an OCT	5
4. Brightness in the outer plexiform layer (OPL)	7
5. A hyperreflective spot in the retina.....	9
6. What is subretinal hyperreflective material (SHRM)?.....	11
7. A bright deep band on OCT	13
8. Don't just look at central macular thickness (CMT)!	15
9. Large white mound under retina	17
10. Where does fluid usually accumulate?.....	19
11. Deep circular rims of hyper-reflectivity.....	21
12. Pigment epithelial detachment (PED) or a rip?.....	23
13. Is hyper-reflectivity in retina always abnormal?.....	25
14. Fluid or normal?.....	27
15. Thickened inner retina.....	29
16. Don't assume that subretinal fluid equals wet age-related macular degeneration....	31
17. Numerous white spots in the retina	33
18. Always look at the choroid in all patients with subretinal fluid (SRF).....	35
19. On every OCT look at the choriocapillaris.....	37
20. Irregular pigment epithelial detachment (PED).....	39
21. A hyperreflective lesion in the superficial retina	42
22. Cystic pigment epithelial detachment (PED).....	44
23. Hyperintense OCT material is not always exudate or hemorrhage.....	46
24. Choroidal neovascular membrane (CNV) with a thin choroid.....	49
25. SRF with PED.....	51
26. Hyperreflective lesions in an overweight middle aged person	53
27. A choroidal elevation.....	55
28. Absence of retinal tissue in fovea.....	57
29. Hyper-reflectivity with posterior vitreous detachment (PVD).....	59
30. Dark intraretinal circles on OCT	61

CONTENTS

31. Central cysts in the retina.....	63
32. Intraretinal cysts following cataract surgery.....	65
33. Outer retinal cysts with crystals.....	67
34. Hole in optic nerve.....	69
35. A yellow lesion in the deep retina.....	71
36. Lamellar bands below the retinal pigment epithelium (RPE).....	73
37. A pigmented lesion near the optic disc.....	76
38. A series of hyper-reflectivity lesions in superficial retina.....	78
39. A flat foveal surface.....	80
40. Bright donuts in inner retina.....	82
41. Bright donuts in inner retina.....	84
42. Hyper-reflectivity in the vitreous.....	86
43. Which eye in the OCT?.....	88
44. Hyper-reflectivity on surface of retina.....	90
45. Look at the choroid on each OCT that you interpret.....	92
46. A bright line on the surface of the retina.....	94
47. Thin central retina with yellow flecks.....	96
48. Look at the choriocapillaris in choroidal elevations.....	98
49. The 3rd Deep Line.....	100
50. A pigment epithelial detachment (PED) with homogenous material.....	102

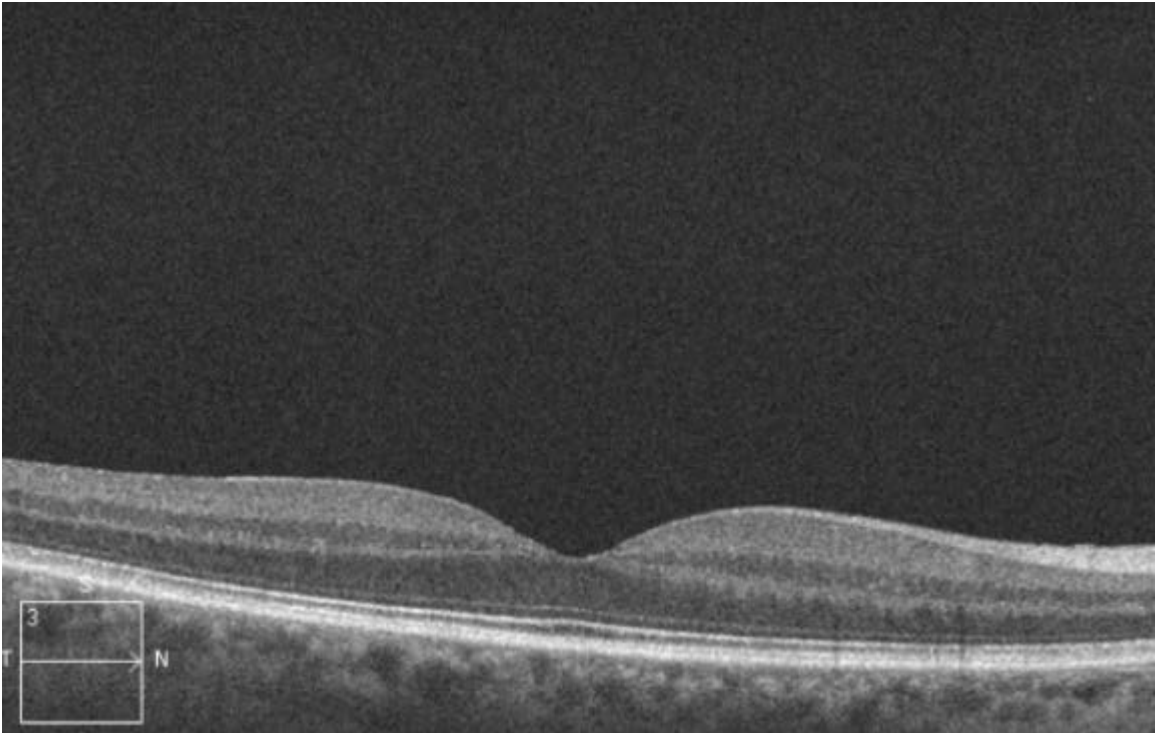
GLOSSARY

AMD	Age-Related Macular Degeneration	MA	Microaneurysm
BMI	Body Mass Index	Mac Tel	Macular Telangiectasis
CME	Cystoid Macular Edema	NFL	Nerve Fiber Layer
CMT	Central Macular Thickness	NVD	Neovascularization of the Disc
CNV	Choroidal Neovascularization	NVE	Neovascularization Elsewhere
COST	Cone Outer Segment	OCT	Optical Coherence Tomography
CRAO	Central Retinal Artery Occlusion	ONL	Outer Nuclear Layer
CSCR	Central Serous Chorioretinopathy	OPL	Outer Plexiform Layer
CWS	Cotton Wool Spots	ORT	Outer Retinal Tubulation
DME	Diabetic Macular Edema	OS	Outer Segment
DPED	Drusenoid Pigment Epithelial Detachment	PDT	Photodynamic Therapy
EDI	Enhanced Depth Imaging	PED	Pigment Epithelial Detachment
ELM	External Limiting Membrane	PVD	Posterior Vitreous Detachment
ERM	Epiretinal Membrane	RAP	Retinal Angomatous Proliferation
EZ	Ellipsoid Zone	RPE	Retinal Pigment Epithelium
FVPED	Fibrovascular Pigment Epithelial Detachment	RVO	Retinal Vein Occlusion
GA	Geographic Atrophy	SD-OCT	Spectral Domain Optical Coherence Tomography
HD Scan	High Definition Scan	SHRM	Subretinal Hyperreflective Material
ILM	Internal Limiting Membrane	SPED	Serous Pigment Epithelial Detachment
INL	Inner Nuclear Layer	SRF	Subretinal Fluid
IPL	Inner Plexiform Layer	VEGF	Vascular Endothelial Growth Factor
IRF	Intraretinal Fluid	VMA	Vitreomacular Adhesion
IRMA	Intraretinal Microvascular Anomalies	VMT	Viteromacular Traction
IS	Inner Segment		

1

THE EXTERNAL LIMITING MEMBRANE (ELM) AND ELLIPSOID ZONE (EZ)

A patient was referred for assessment given a family history of cone dystrophy. Do you think that there is a dysfunction of the cones?



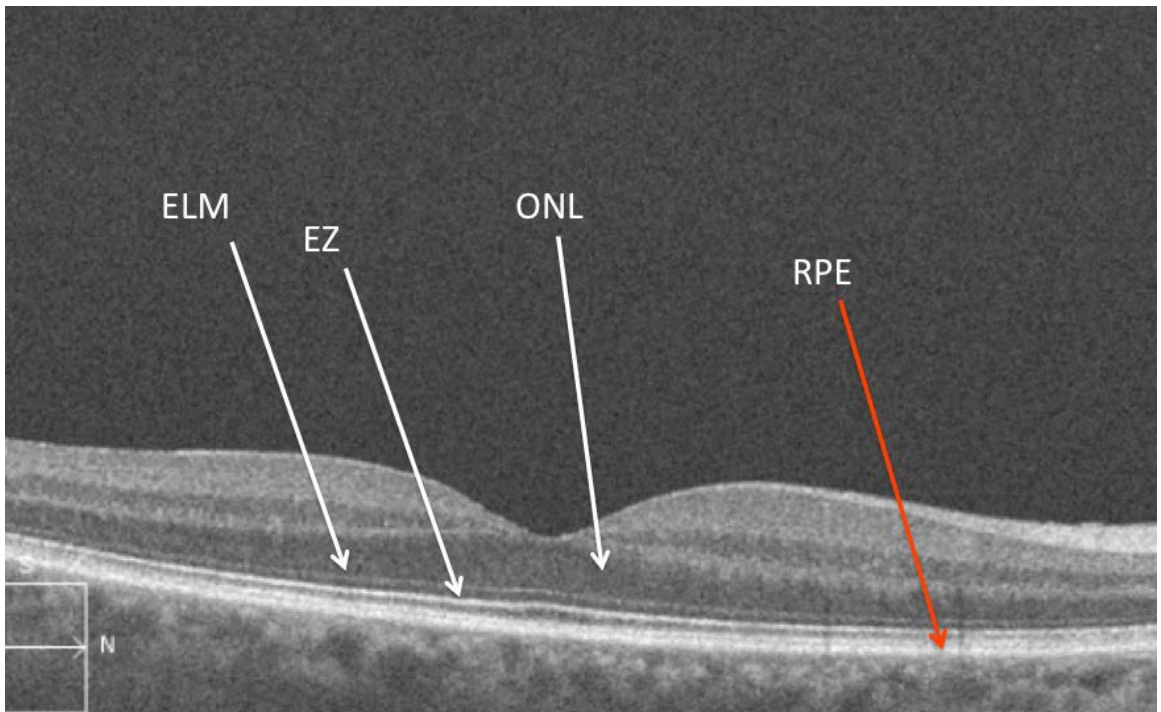
Analysis

In the deepest layers of the retina there are typically 3 visible bands. The most anterior band is the external limiting membrane (ELM). This layer is located between the outer nuclear layer (ONL) and the photoreceptor inner segments. The ELM is made up of junctional complexes between Muller cells and the photoreceptors. The second line, called the ellipsoid zone (EZ), is the bright line anterior to the Retinal Pigment Epithelium (RPE). This zone is the junction between the inner and outer segments of the photoreceptors (IS/OS junction), and is believed to consist of the mitochondria located in the outer portion of the inner segments of the photoreceptors. The third layer consists of an amalgam of the cone outer segments as they interdigitate with the RPE cells.

Usually, the distance between the ELM and the EZ is significantly less than the distance between the EZ and the RPE.

It is also important to note that there is a significant correlation between the degree to which the ELM and EZ are intact and a patient's visual acuity. It can be disrupted in conditions arising from the deep retina, such as AMD, as well as inherited ones, such as dystrophies of the photoreceptors.

In this patient the ELM, EZ, and RPE are all intact. The ONL is also very robust and healthy looking. Both of these are not there is no sign of this condition on the OCT.



OCT Tip

The first bright line in the outer retina is the ELM and the second is the EZ; both are correlated with visual acuity.

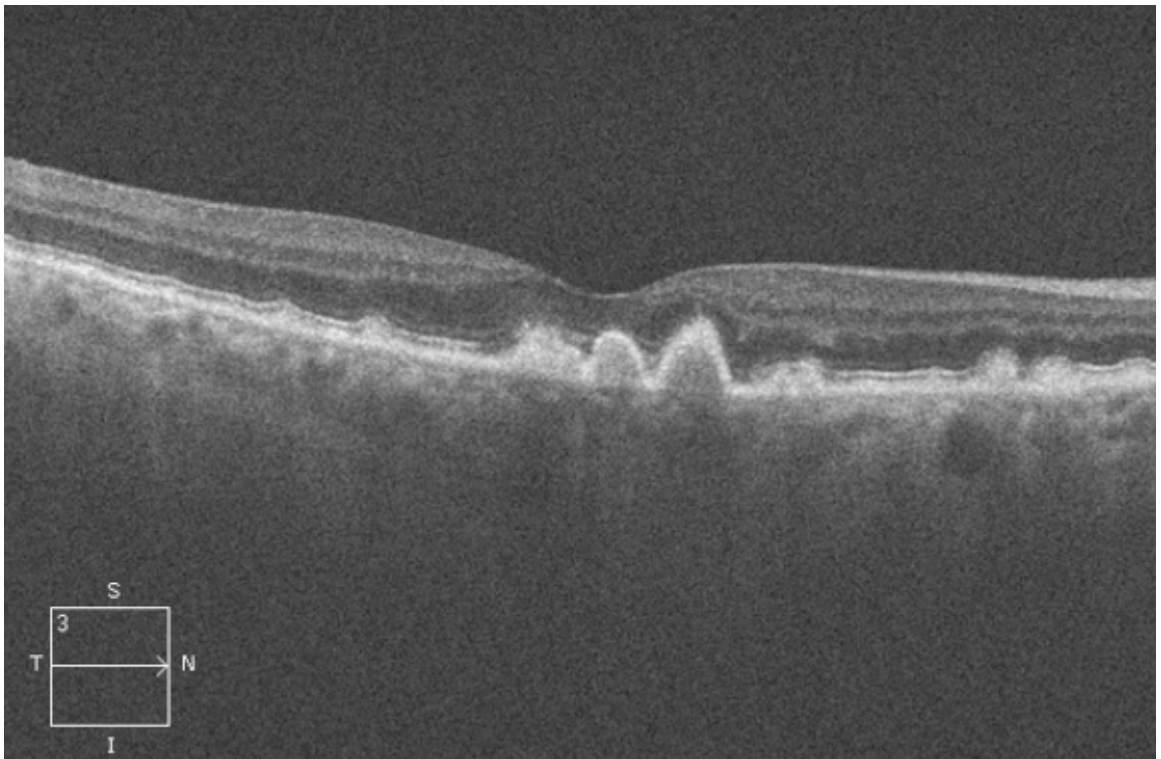
Suggested follow-up/referral

As all layers of the retina are within normal limits, referral is not needed. Given the family history, annual assessment is recommended.

2

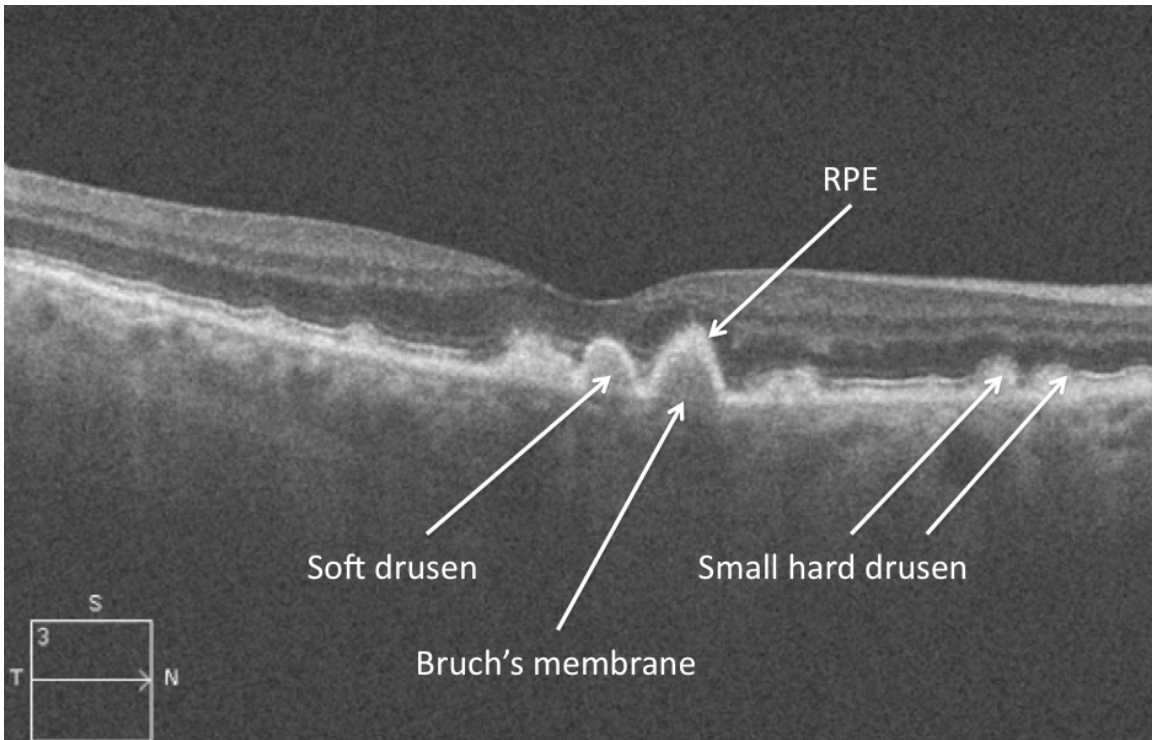
RETINAL PIGMENT EPITHELIUM (RPE) BUMPS

A 42-year-old presents for the first time with complaints of “having to move the computer back further to read fine print.” The symptoms are alleviated with low powered reading glasses. You examine the retina and notice some abnormalities. An OCT is shown below. What do you see?



Analysis

Drusen are deposits located just beneath the retinal pigment epithelium (RPE) and in Bruch's membrane, and are visible on OCT's as elevation and thickening of the RPE. Drusen consist of material that is heterogeneous in nature and appears hyperreflective on OCT. Deep to the drusen, Bruch's membrane may or may not be visible. In this image, both small hard drusen (visualized as small hyperintense lesions that are indistinguishable from the RPE and Bruch's membrane), and soft larger drusen (which are elevations of RPE from Bruch's membrane, with medium to high hyper-reflectivity located under the RPE) are present.



OCT Tip

If you see bumps at the level of the RPE, drusen are usually present.

Suggested follow-up/referral

This case is at high risk for conversion to wet age-related macular degeneration (wet AMD) and should be closely monitored (every 4-6 months) for conversion to wet AMD.